

ORAL LACERATIONS

Level II

Skill Level: RN

Definition: A disruption in the integrity of the oral mucosa which may include the skin area outside the vermilion border (the junction of the pinkish-red area of the lips with the surrounding skin).

<p>Subjective:</p> <ul style="list-style-type: none">• "I was hit in the mouth."• "I'm bleeding."• " I have a cut in my mouth"	<p>Assessment:</p> <ul style="list-style-type: none">• An alteration in the oral mucosa and/or lip.• An alteration in comfort.• An alteration in nutrition.
<p>Objective:</p> <ul style="list-style-type: none">• Interoral or extraoral laceration with moderate to heavy bleeding.• Laceration is greater than 6mm.• Lacerations of the face outside the vermilion border of the lip are not covered under this protocol.	<p>Plan:</p> <p>Call the Dental Clinic and send the patient immediately to the dentist if possible. Check other institutions, if possible, to see if a dentist is available.</p> <p>If no dentist is available, the patient will need to be sent for suturing if any of the following exist:</p> <ul style="list-style-type: none">• Intraoral laceration on the attached gingiva (hard gum tissue) greater than one cm in length. (**See picture and nursing education)• Any laceration if direct pressure will not stop bleeding within 15-30 minutes.• Laceration of the outside of the lip greater than one cm in length.• Laceration of the lip that crosses the vermilion border (onto the facial skin).• Mucosal lesions in the mouth, even when large or involving the inner surface of the lip will usually heal uneventfully without suturing as long as they do not involve any bony structures.• Call the dentist or medical provider on call if you have questions about whether or not the patient needs to be sent out for suturing.

At nursing discretion may use any of the following:

- Control bleeding with gauze or a teabag if available.
- Gently clean the area.
- Suggest salt water rinses TID prn.
- Antibiotics may be used to help prevent infection:
 - Amoxicillin 500 mg TID for 7 days.
 - If allergic to Amoxicillin, EES 800 mg BID for 7 days may be used as long as there is no sign of infection.
- Instruct patient to use meds available on the housing unit to treat pain (handout).
- If available meds not effective, may use Ketoprophen 75 mg TID for 5 days instead. (Always second line.)
- May order soft diet.
- Assess need for Tetanus vaccine.

Nursing education:

**Even small lacerations of the attached gingiva (light pink labeled labial mandibular or maxillary gingival in the diagram) frequently need to be sutured. The labial mucosa (darker pink) frequently does not need to be sutured. See attached diagram.

APPROVED:

Health Service Manager

Date

12/15/08

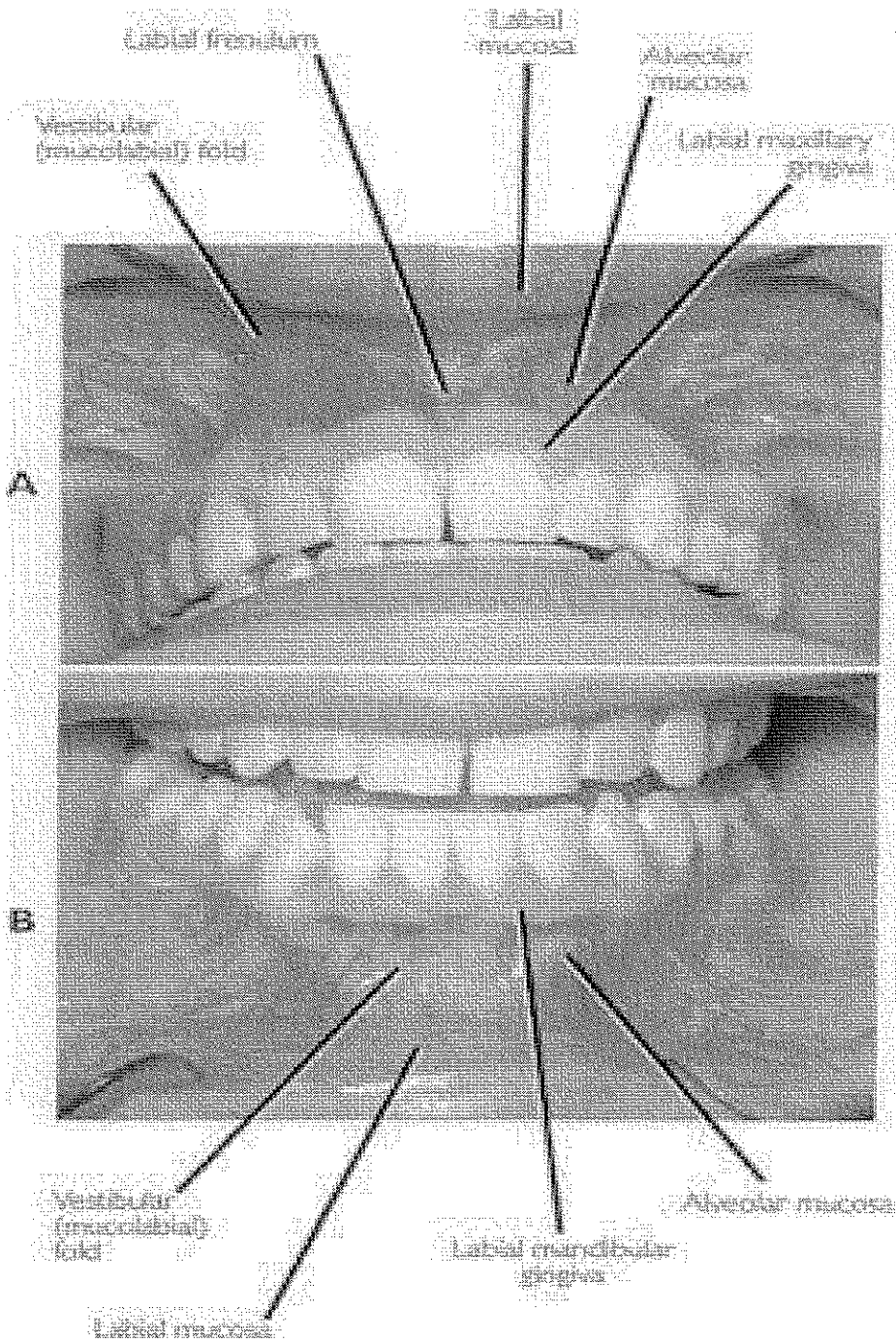
Dental Director

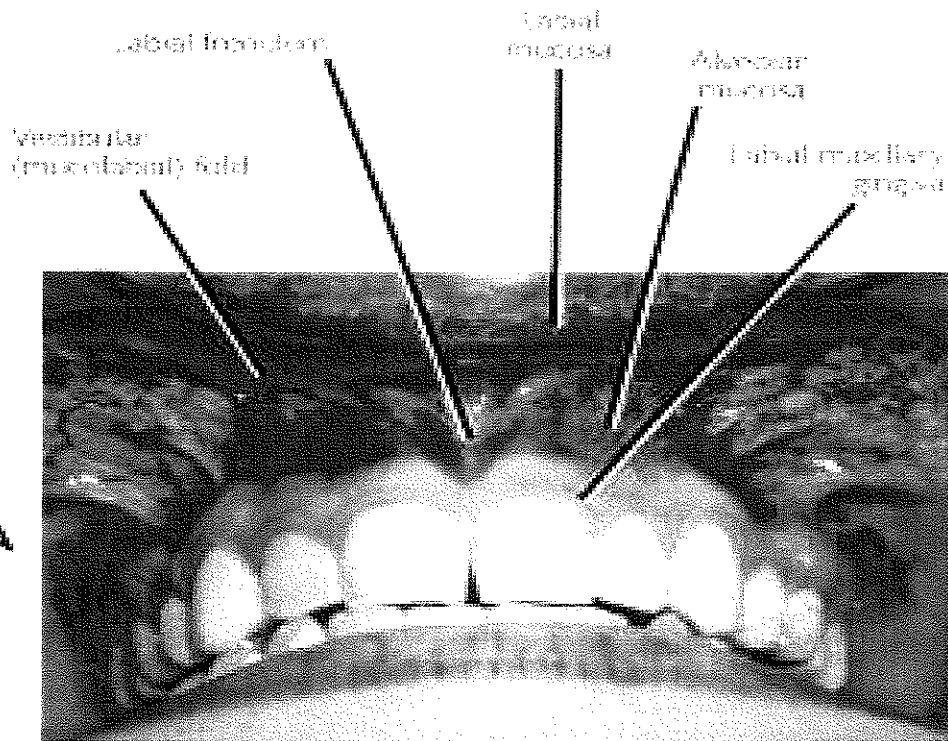
Date

11/17/08

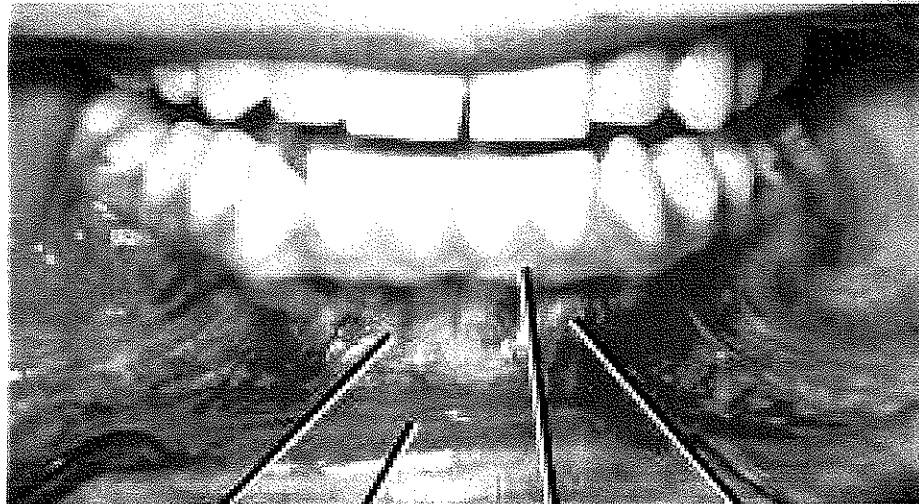
Medical Director

Date





A



B

Dental Coverage by Institution

The following institutions frequently do not have dental staff in the building. Here is the coverage pattern to use if your dental staff members are not available and you need to get in touch with somebody on an urgent basis.

Institution

Warner Creek Correctional Facility

Deer Ridge Correctional Institution

Shutter Creek Correctional Institution,
Mill Creek Correctional Facility, and
or Oregon State Penitentiary (Minimum only)

South Fork Forest Camp

Coverage

Snake River Correctional Institution

Two Rivers Correctional Institution

Oregon State Correctional Institution
Santiam Correctional Institution

Columbia River Correctional
Institution